

PennHIP Report

Referring Veterinarian: Dr Dagmar Schouten
Email: rpalmer@cedarwoodvet.ca

Clinic Name: Cedarwood Veterinary Hospital
Clinic Address: 7644 Gaetz Ave
Red Deer, AB T4P 2A8
Phone: (403) 347-2676
Fax: (403) 346-9925

Patient Information

Client: Topping, Lauren
Patient Name: Ellie
Reg. Name: UNTINEN ELLIE JO
PennHIP Num: 186204
Species: Canine
Date of Birth: 15 Sep 2020
Sex: Female
Date of Study: 09 Mar 2023
Date of Report: 14 Mar 2023

Tattoo Num:
Patient ID: 211357
Registration Num: UTM7188G
Microchip Num: 952000001258887
Breed: MAREMMA SHEEPDOG
Age: 30 months
Weight: 83.3 lbs/37.8 kgs
Date Submitted: 09 Mar 2023

Findings

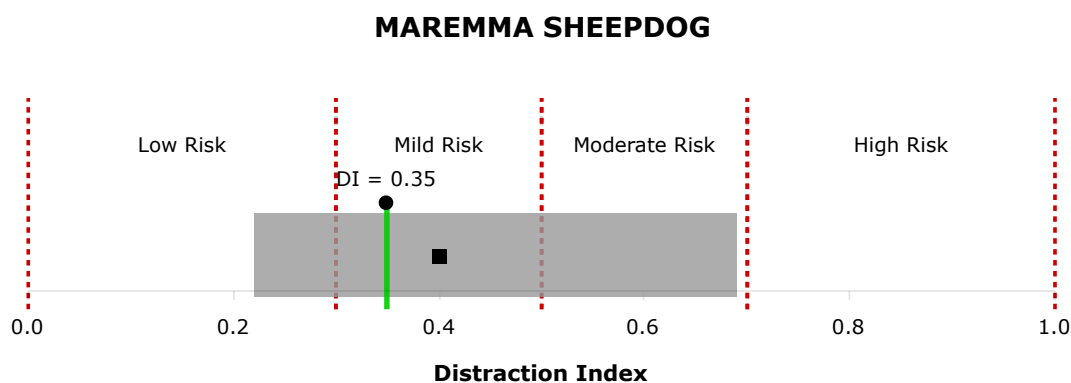
Distraction Index (DI): Right DI = 0.30, Left DI = 0.35.
Osteoarthritis (OA): **No radiographic evidence of OA for either hip.**
Cavitation/Other Findings: No cavitation present.

Interpretation

Distraction Index (DI): The laxity ranking is based on the hip with the greater laxity (larger DI). In this case the DI used is 0.35.

OA Risk Category: The DI is between 0.31 and 0.49. This patient is at mild risk for hip OA.

Distraction Index Chart:



BREED STATISTICS: This interpretation is based on a cross-section of 234 canine patients of the MAREMMA SHEEPDOG breed in the AIS PennHIP database. The gray strip represents the central 90% range of DIs (0.22 - 0.69) for the breed. The breed average DI is 0.40 (solid square). The patient DI is the solid circle (0.35).

SUMMARY: The degree of laxity (DI = 0.35) falls within the central 90% range of DIs for the breed. This amount of hip laxity places the hip at a mild risk to develop hip OA. **No radiographic evidence of OA for either hip.**